



Advantages and Disadvantages in Image Processing with Free Software in Radiology

Katrin Muradas Mujika¹ · Juan Antonio Juanes Méndez² · Andrés Framiñan de Miguel¹

Received: 5 December 2017 / Accepted: 22 December 2017 / Published online: 15 January 2018
© Springer Science+Business Media, LLC, part of Springer Nature 2018

Abstract

Currently, there are sophisticated applications that make it possible to visualize medical images and even to manipulate them. These software applications are of great interest, both from a teaching and a radiological perspective. In addition, some of these applications are known as Free Open Source Software because they are free and the source code is freely available, and therefore it can be easily obtained even on personal computers. Two examples of free open source software are Osirix Lite® and 3D Slicer®. However, this last group of free applications have limitations in its use. For the radiological field, manipulating and post-processing images is increasingly important. Consequently, sophisticated computing tools that combine software and hardware to process medical images are needed. In radiology, graphic workstations allow their users to process, review, analyse, communicate and exchange multidimensional digital images acquired with different image-capturing radiological devices. These radiological devices are basically CT (Computerised Tomography), MRI (Magnetic Resonance Imaging), PET (Positron Emission Tomography), etc. Nevertheless, the programs included in these workstations have a high cost which always depends on the software provider and is always subject to its norms and requirements. With this study, we aim to present the advantages and disadvantages of these radiological image visualization systems in the advanced management of radiological studies. We will compare the features of the VITREA2® and AW VolumeShare 5® radiology workstation with free open source software applications like OsiriX® and 3D Slicer®, with examples from specific studies.

Keywords Imaging diagnosis · Free open source software · Osirix lite® · 3D slicer® · Workstation · Vitrea2® · AW VolumeShare 5®

Introduction

Over the last years, new technological applications make it possible to visualize and manipulate medical images, some of them without any cost. These software applications need

to be sophisticated because nowadays there is not only 2D–image information. Radiologists and the medical society in general prefer to see images in 3D, which allow them to see the anatomy and some disorders more easily. Image post-processing procedures must be carried out by the radiologist in order to obtain more information to help with diagnosis and even to act as a guide for the surgical approach.

Software applications that are free and open-source are an alternative for working with medical images compared with software applications which are installed in the radiology workstation and are very expensive and difficult to obtain. Osirix lite and 3D Slicer are examples of free open source software applications that are well known in the radiology community. These applications make possible to overcome the limitations of traditional methods and promote the participation and interaction of students, interns and specialists with the imaging contents obtained with these new tools [1].

Our objective is to compare the open source free software with the applications used in the radiology workstation to see

This article is part of the Topical Collection on *Education & Training*

✉ Katrin Muradas Mujika
katrin.muradas@gmail.com

Juan Antonio Juanes Méndez
jajm@usal.es

Andrés Framiñan de Miguel
frami@usal.es

¹ University Healthcare Complex of Salamanca, Paseo San Vicente 58-182, 37007 Salamanca, Spain

² School of Medicine, VisualMed System Group, University of Salamanca, Avda. Alfonso X el Sabio s/n, 37007 Salamanca, Spain

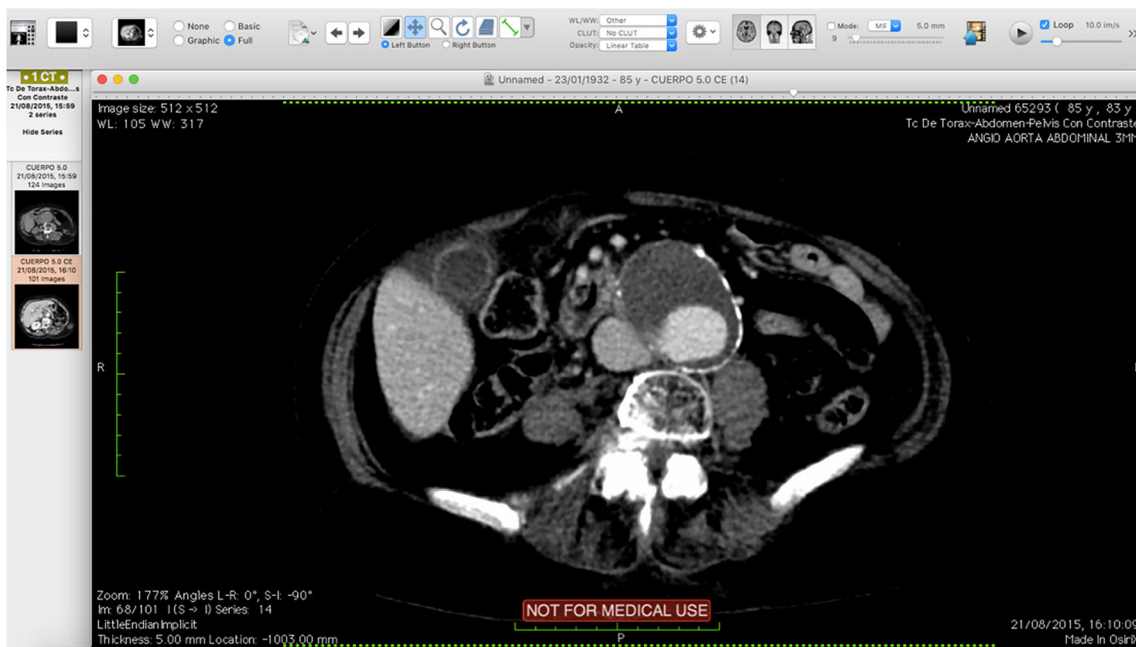


Fig. 1 Angio-CT study with postprocessing for a study of the abdominal aorta and iliac artery to assess their permeability with VITREA2®

the advantages and disadvantages of the free programs. And, consequently, to determine whether open source software applications are a suitable alternative for the analysis of images and for students to learn.

Materials and Methods

First of all, and in order to carry out our analysis, we have chosen 5 patients with or without different pathologies

from the University Healthcare Complex of Salamanca. We obtained all their imaging information from CT and MRI (1.5 T) studies that were stored in the PACS (Picture archiving and communication system) using the DICOM format (Digital Imaging and Communication in Medicine), which is a global standard for exchanging, handling, visualizing, storing, printing and transmitting medical images.

We have chosen two free open source software programs which were running on a Macintosh OS (Macbook Air, CPU

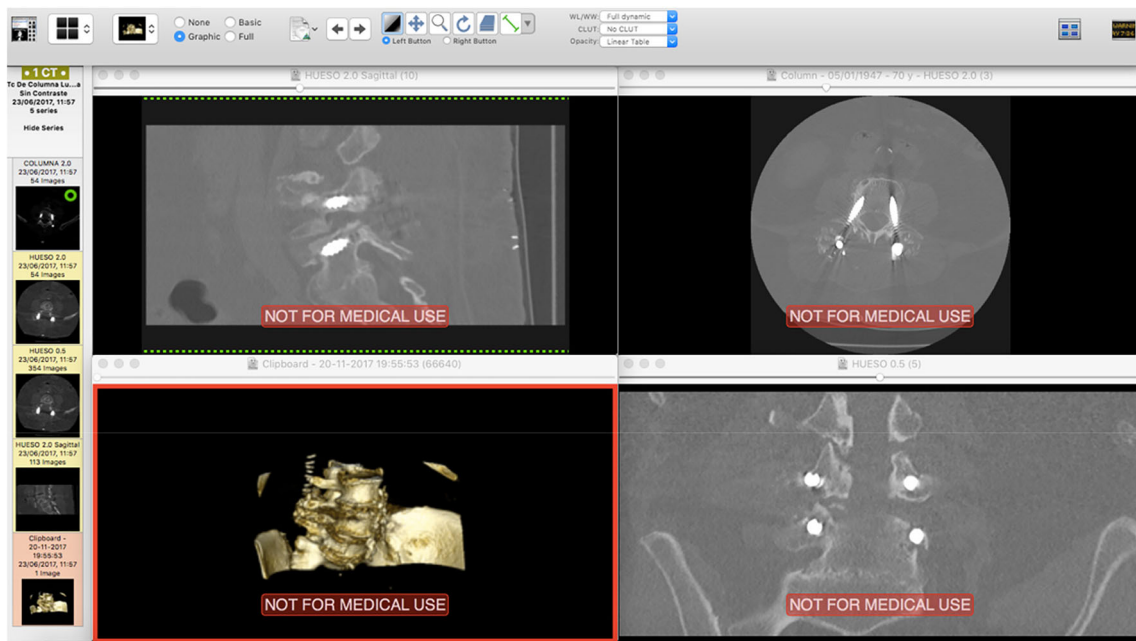


Fig. 2 Lumbosacral spine study after L4-L5 fusion with OsiriX Lite software

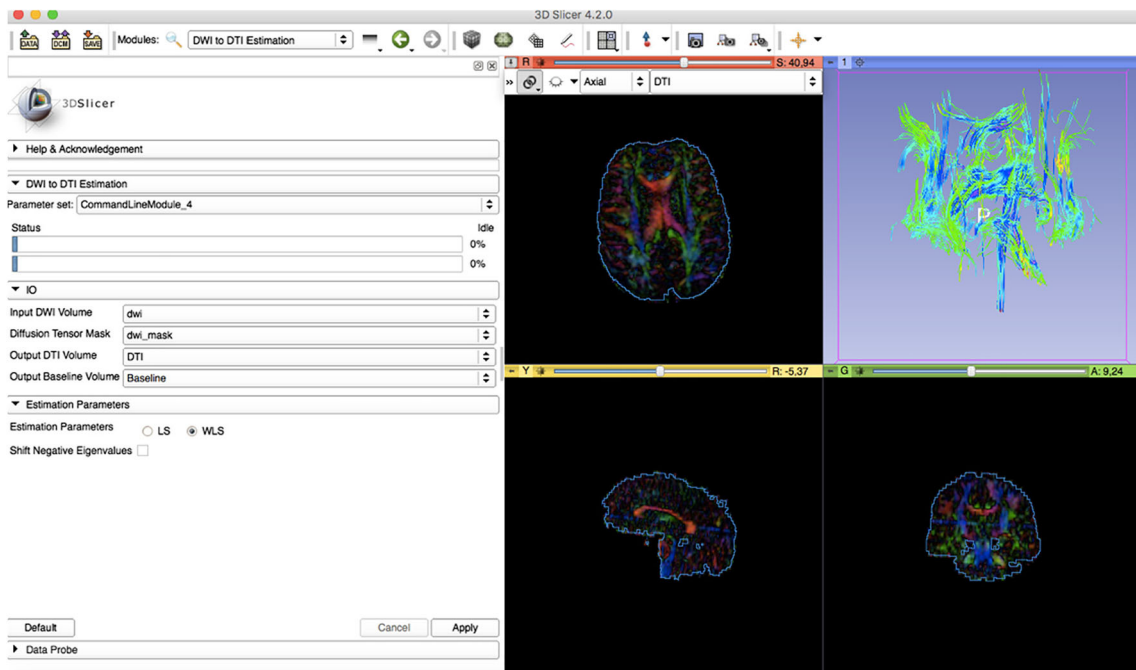


Fig. 3 Image processing to obtain a tractography image with 3D Slicer

at 2 GHz, 8 GB RAM, 32 bit OS): Osirix lite version 8.0.2 (www.osirix-viewer.com) and 3D Slicer version 4.2 (www.slicer.org). The first one was developed by the Department of Radiology and Medical Informatics of the University Hospital of Geneva in collaboration with the University of California at Los Angeles (UCLA). The other open source software program was developed by Slicer Community over 15 years ago.

The hospital workstation is a Microsoft computer with a Windows operating system. It contains Vitrea2® version 4.1.14.0 from Toshiba medical systems. It is a medical diagnosis system which allows its users to process, analyse and review the images, as well as to transmit and exchange multiplanar digital images. Additionally, we have used AW VolumeShare 5® (AW4.6) from General Electric to achieve tractography images.

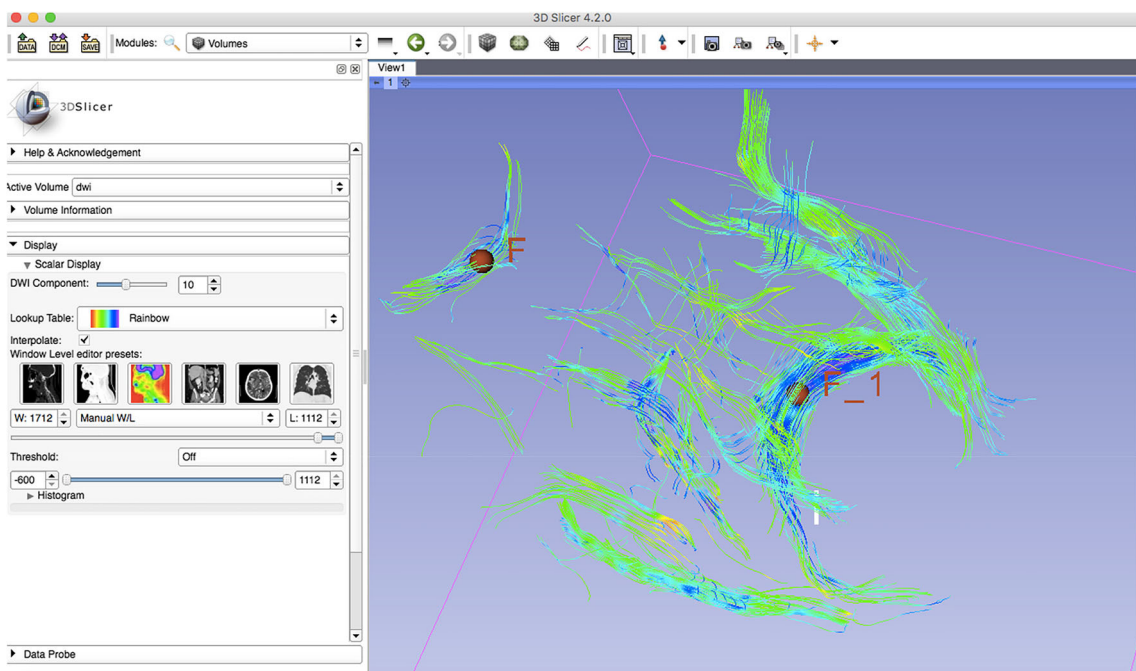


Fig. 4 Image processing to obtain a tractography image with 3D Slicer




Fig. 5 Representation of a tractography image in a patient with a tumor brain with AW VolumeShare 5®

In order to compare the free open source software programs with the applications which are included in the workstation of our hospital, we have used the same DICOM format from those 5 patients. First, we have processed and analysed the images on the free software programs and then on the workstation.

Moreover, we have done a literature search on Pubmed with the terms “Imaging diagnosis”, “Free Open Source Software”, “Osirix lite” and “3D Slicer” as keywords in order

to obtain more information about free open source software programs.

We have used the manual called “Diffusion Tensor Imaging Tutorial” for 3D Slicer, which was obtained from their web.

Results and Discussion

Free Open Source Software Programs

Free Open Source software is a system that offer the freedom of using, studying, sharing, and modifying that software to its users. Although it is a new and recent concept in the medical community [2], there are different open source software applications which make it possible to manage medical images. There are currently over 150 diagnostic applications available. Despite this large range of possibilities, each of these applications have different qualities which may make them more or less useful, depending on our needs.

According to the advice published by Valeri G. et al. (2014) [3], in an article analyzing over 40 software applications, we have decided to use the two most recommended programs,

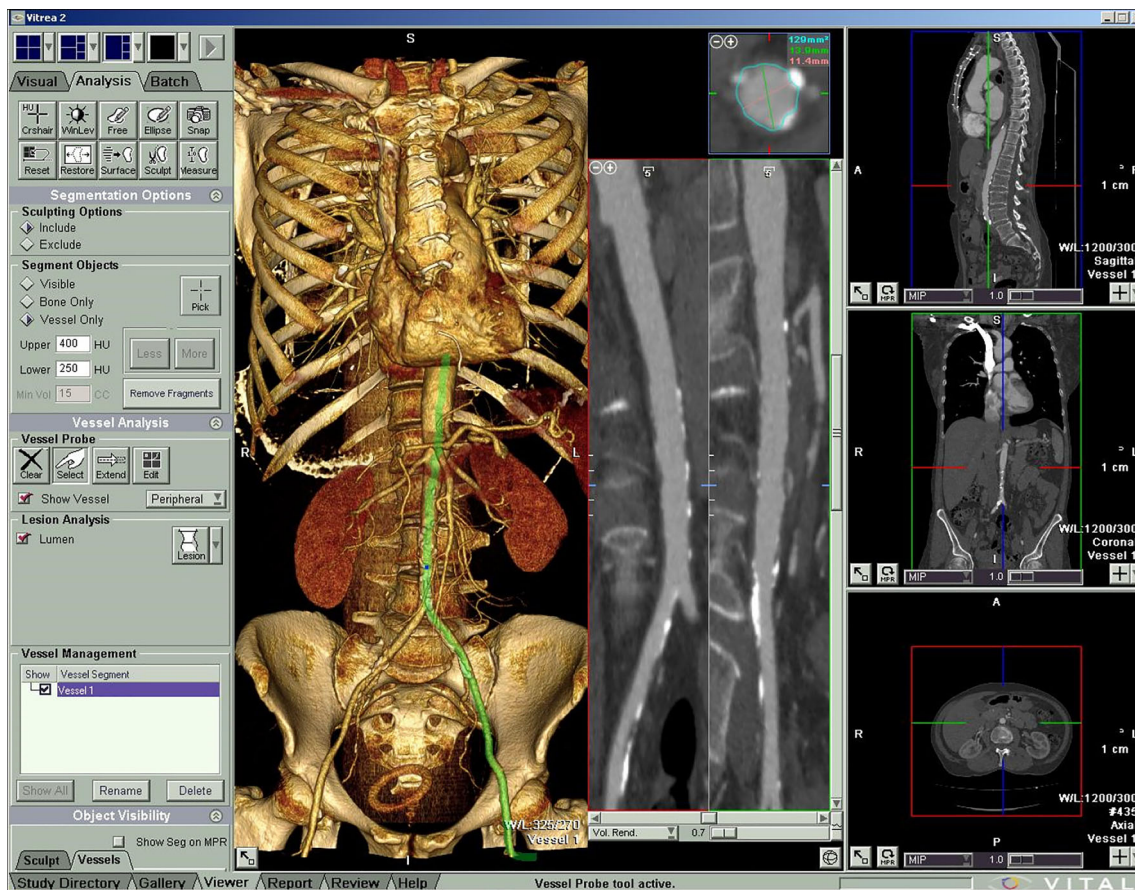


Fig. 6 Angio-CT study with postprocessing for a study of the abdominal aorta and iliac artery to assess their permeability with VITREA2®

due to the wide range of computing requirements they met and the image post-processing options they offered. Therefore, we will present a comparison between these two programs and the workstation that is used in our hospital.

OsiriX Lite

OsiriX lite was the first program we chose for a comparative study with the workstation. It was our first choice because we already had experience with it. Also, according to Valeri G. et al., it is one of the most complete free software programs. It is one of the best-known software applications and has been adapted for MacOS and iOS, although it has not been adapted for Windows XP. It uses the DICOM format which makes it possible to transfer images from the workstation to the application easily. Unlike many other programs, it makes it possible to post-process the images and to achieve a volumetric analysis which can be configured to obtain MPR (Multiplanar Reconstruction) MIP (Maximum Intensity Projection), and 3D images. This can be seen in Fig. 1, which shows an aortic dissection in different projections with good image quality.

In addition, using a 3D processing we demonstrate that there is a good correlation between the information provided

by OsiriX and the normal anatomy. Consequently, it is very useful for surgical planning and guidance during the operation [4–6], as well as for students as a support for the anatomy study. Figure 2 presents a postoperative lumbar image. The 3D images make it possible to see whether the surgical material is placed correctly. Compared with VITREA2, the quality of the image seems similar. In our experience, MPR studies are very adequate and provide good definition.

However, the free version of the software (OsiriX lite) is more limited. It is not certified for use as a first diagnosis. In order to use it as a working tool and for diagnostic purposes, it is necessary to purchase OsiriX MD, which is commercial software under license [3]. In addition, there are some features which are not available in the free version, and in these cases, it is necessary to download OsiriX MD.

Moreover, while working with OsiriX lite, an advertisement to buy their commercial software pops up, and this makes the experience rather annoying.

3D Slicer

Our second option, 3D Slicer, is a free open source software platform for medical images which can process them and

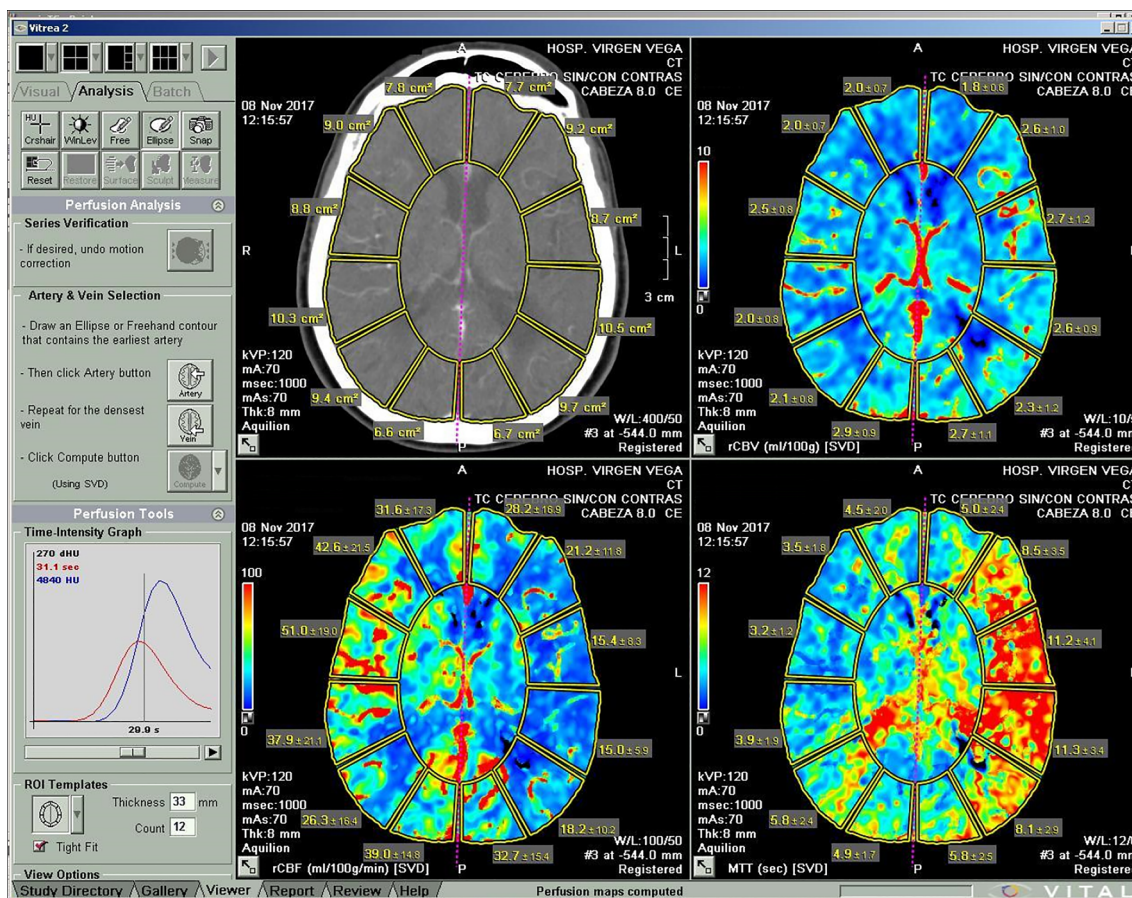


Fig. 7 Perfusion study to assess brain parenchymal viability with VITREA2®

show 3D studies. The latest version is 4.6, but we have used version 4.2 because our team was already familiarized with it. One of the options offered by this software which is not included in other programs is the possibility to obtain diffusion tensor imaging from diffusion weighted images [7], and it provides estimates and generates images of neural fibres (Figs. 3 and 4).

In addition, one of its strong points is that it is able to generate tractography images without previously processing them in the hospital workstation [8]. It is very useful for the students in order to learn more about neuronal fibre tracts. However, the process to obtain tractography images is complex and it is necessary to spend several minutes working on it, because it is not as intuitive as AW VolumeShare 5®. One of the steps that is necessary to do in order to obtain a DWI format for weighting the tracts, is to convert DTI in DWI which is quite complicated.

Workstation

The University Hospital of Salamanca uses VITREA2® and AW VolumeShare 5®. Some examples of the work that can be done with this device are tractography studies, which offer a better view of the main neural paths so that neurosurgery can

be planned more accurately by locating the tumor and the neural paths affected depending on the approach [9, 10] (Fig. 5), and even make it possible to assess neurodegenerative diseases. It can also be useful for students to learn about the main neural paths more easily, as well as automated vascular measurement, which provides information for vascular surgeons prior to surgery [11] (Fig. 6); brain perfusion scan to assess how much brain tissue is viable after a stroke [12] (Fig. 7), and which will make it possible to take a decision on the start of anticoagulation therapy. This software is also useful to make 3D reconstructions of the skeleton (Fig. 8).

However, there are also some disadvantages, mainly its high cost, which makes it difficult to acquire the software for individual use, particularly in public hospitals in which funding may be lower. Also, the software can only be accessed by one user per licence. This, together with its price, leads to a major restriction for the daily activity of the unit.

Conclusions

The two free applications that have been analyzed, Osirix lite® and 3D Slicer®, have advantages and disadvantages

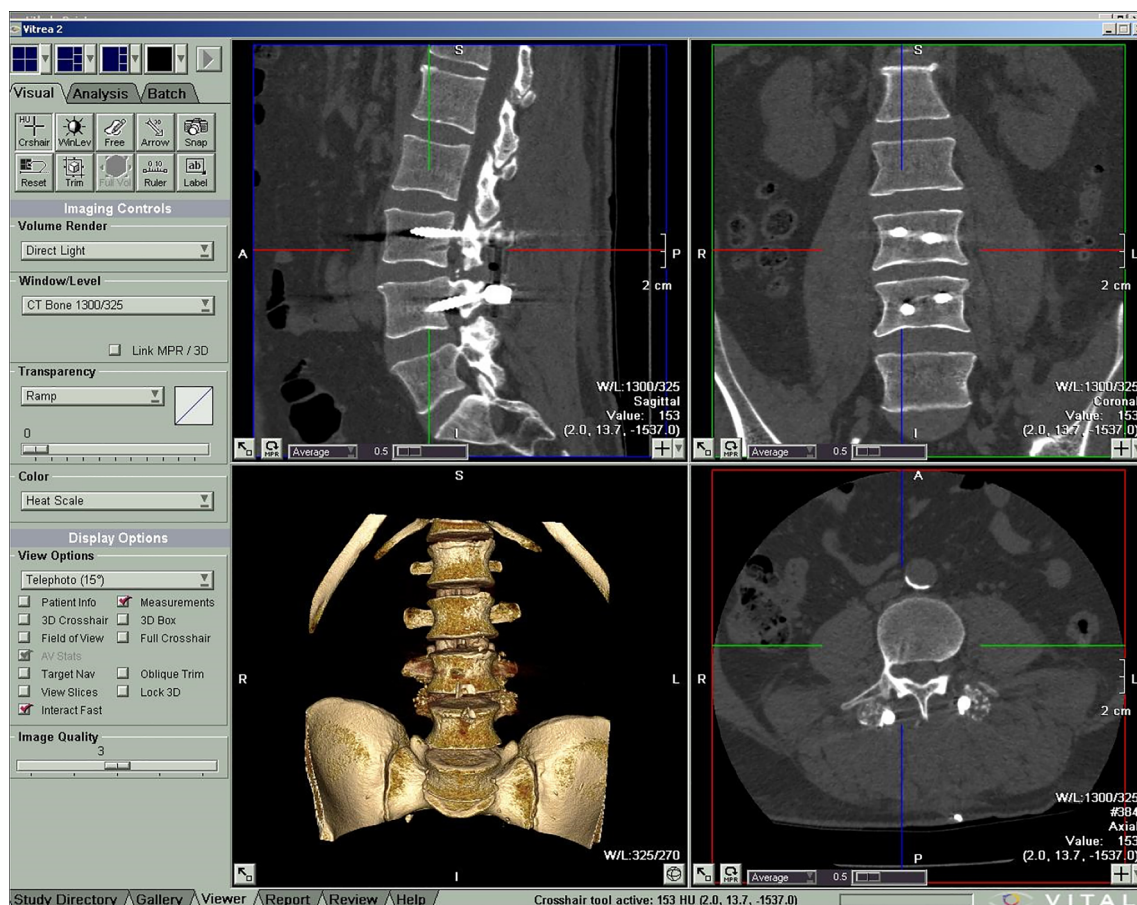


Fig. 8 Lumbar spine study after L3-L4-L5 fusion with Vitrea2®

compared to the application of the workstation, which uses Vitrea2® and AW VolumeShare5®.

Free software may be a good alternative to workstations, which involve spending large amounts of money. Also, we have seen that the software analysed here presents many of the functions required for radiological diagnosis. However, free software has some limitations on its choice of image processing. Another handicap of these programs, perhaps more importantly, is that they must be accompanied by a quality certification which is not always included. If it cannot be purchased, the programs cannot be used for diagnostic purposes [3], although they may be used for training purposes.

From our point of view, a workstation is needed for radiologists to acquire information, especially for the first diagnosis. But if the purpose is to study and practice with the images, free open source software could be the best choice.

One of our purposes in the future is to demonstrate that 3D Slicer is reliable to guide the neurosurgical process compared to AW VolumeShare 5®. Another idea for future analysis is to see if students would be satisfied with these programs to learn more about anatomy and also for some pathologies.

Compliance with Ethical Standards

Conflict of Interest K. Muradas Mujika declares that she has no conflict of interest. J.A. Juanes Méndez declares that he has no conflict of interest. A. Framiñán de Miguel declares that he has no conflict of interest.

Ethical Approval This article does not contain any studies with human participants or animals performed by any of the authors.

References

- Juanes, J.A., Ruisoto, P., Prats, A., and Framiñán, A., Open source applications for image visualization and processing in neuroimaging training. *J Inform Technol Res.* 7(2):75–87, 2014. <https://doi.org/10.4018/jitr.2014040107>.
- Karopka, T., Schmuhl, H., and Demski, H., Free/libre open source software in health care: A review. *Healthc Inform Res.* 20(1):11–22, 2014. <https://doi.org/10.4258/hir.2014.20.1.11>.
- Valeri, G., Mazza, F.A., Maggi, S., Aramini, D., La Riccia, L., Mazzoni, G., and Giovagnoni, A., Open source software in a practical approach for post processing of radiologic images. *Radiol Med.* 120(3): 309–323, 2015. <https://doi.org/10.1007/s11547-014-0437-5>.
- Lo Presti, G., Carbone, M., Ciriaci, D., Aramiri, D., Ferrari, M., and Ferrari, V., Assessment of DICOM viewers capable of loading patient-specific 3D models obtained by different segmentation platforms in the operating room. *J Digit Imaging.* 28:518–527, 2015. <https://doi.org/10.1007/s10278-015-9786-4>.
- Sierra, M.E., Cienfuegos, M.R., and Fernández, S.G., OsiriX, a useful tool for processing tomographic images in patients with facial fracture. *Cir Cir.* 77(2):95–99, 2009.
- Yamauchi, T., Yamazi, M., Okawa, A., Furuya, T., Hayashi, K., Sakuma, T., Takahashi, H., Yanagawa, N., and Koda, M., Efficacy and reliability of highly functional open source DICOM software (OsiriX) in spine surgery. *Neuroradiology Report J of Clinical Neuroscience.* 17(6):756–759, 2010. <https://doi.org/10.1016/j.jocn.2009.09.037>.
- Fedorov, A., Beichel, R., Kalpathy-Cramer, J., Finet, J., Fillion-Robin, J.C., Pujol, S., Bauer, C., Jennings, D., Fennessy, F., Sonka, M., Buatti, J., Aylward, S., Miller, J.V., Pieper, S., and Kikinis, R., 3D slicer as an image computing platform for the quantitative imaging network. *Magn Reson Imaging.* 30(9):1323–1341, 2012. <https://doi.org/10.1016/j.mri.2012.05.001>.
- Kikinis, R., and Pieper, S., 3D slicer as a tool interactive brain tumor segmentation. *Conf Proc IEEE Eng Med Biol Soc.* 2011:6982–6984, 2011. <https://doi.org/10.1109/IEMBS.2011.6091765>.
- Golby, A.J., Kindlmann, G., Norton, I., Yarmarkovich, A., Pieper, S., and Kikinis, R., Interactive diffusion tensor tractography visualization for neurosurgical planning. *Neurosurgery.* 68(2):496–505, 2011. <https://doi.org/10.1227/NEU.0b013e3182061ebb>.
- Jellison, B.J., Field, A.F., Medow, J., Lazar, M., Salamat, M.S., and Alexander, A.L., Diffusion tensor imaging of cerebral white matter: A pictorial review of physics, fiber tract anatomy, and tumor imaging patterns. *AJNR Am J Neuroradiol.* 25:356–369, 2004.
- Laghi, A., Catalano, C., Iannaccone, R., Paolantonio, P., Panebianco, V., Sansoni, I., Trenna, S., and Passariello, R., Multislice spiral CT angiography in the evaluation of the anatomy of splanchnic vessels: Preliminary experience. *Radiol Med.* 102(3): 127–131, 2001.
- Copen, W.A., Schaefer, P.W., and Wu, O., MR perfusion imaging in acute ischemic stroke. *Neuroimaging Clin N Am.* 21(2):259–283, 2011. <https://doi.org/10.1016/j.nic.2011.02.007>.