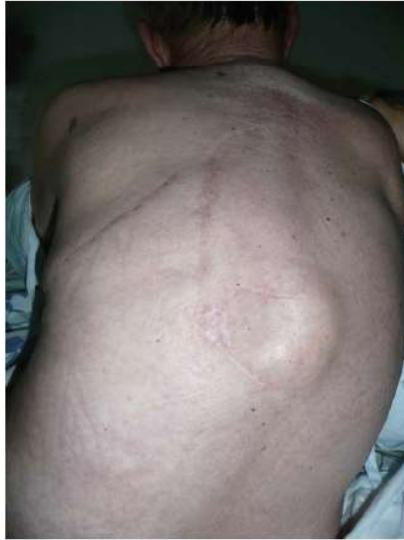

## Medical Imagery

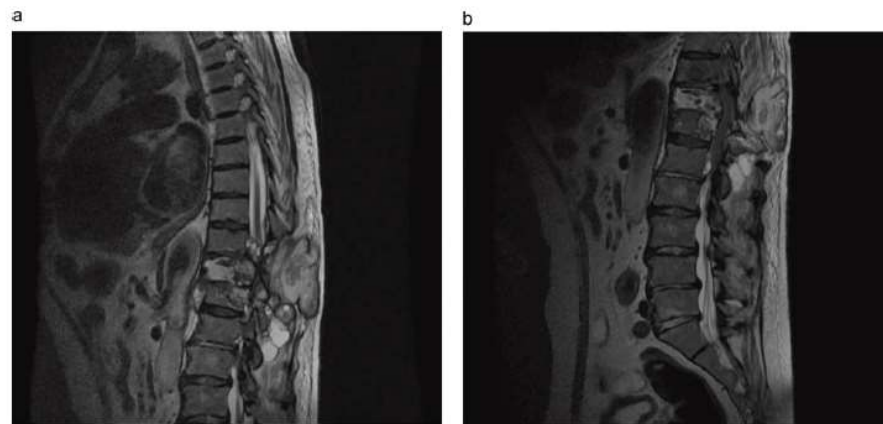
## Recurrent spinal echinococcosis



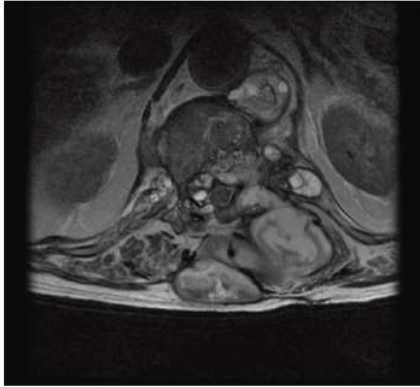**Figure 1.** On examination, a fluctuant mass (6 × 6 cm) was observed on the back of the patient.

A 74-year-old man presented with paraparesis and a painful mass on his back of 4 weeks duration. He had been operated on for thoracic and vertebral hydatidosis (T10–L1 levels) 5 years previously, and had been treated with albendazole and praziquantel for 1 year with a full recovery. Physical examination revealed post-surgery scars and a new dorsal mass (6 × 6 cm) (Figure 1), paraplegia, paresthesia with no sensitive level, and decreased anal sphincter tone. Laboratory data showed elevated C-reactive protein (26.1 mg/l). The white cell count was  $12.4 \times 10^9/l$  without eosinophilia. Serologic tests for hydatid disease had increased. Magnetic resonance imaging of the dorsal and lumbar spine showed a paravertebral mass with destruction of T11, intraspinal invasion, and medullary compression (Figures 2 and 3). The final diagnosis was recurrent spinal echinococcosis with medullary involvement. He was rejected for surgery due to secondary complications. He received medical treatment (antiparasitic drugs and steroids) with little clinical improvement and finally died due to urinary sepsis.

*Conflict of interest:* No potential conflict of interest relevant to this article.



**Figure 2.** Sagittal section MRI shows a paravertebral mass with destruction of T11, intraspinal invasion, and medullary compression.



**Figure 3.** Transverse section MRI shows a paravertebral mass with destruction of T11, intraspinal invasion, and medullary compression.

Moncef Belhassen-García<sup>a,\*</sup>

Adela Carpio-Perez<sup>a</sup>

Juan Francisco Blanco<sup>b</sup>

Virginia Velasco-Tirado<sup>a</sup>

Javier Pardo-Lledías<sup>c</sup>

<sup>a</sup>Department of Internal Medicine, Tropical Diseases Research Center (CIETUS), University Hospital of Salamanca, Paseo San Vicente 58-182, Salamanca, Spain

<sup>b</sup>Department of Orthopedics, University Hospital of Salamanca, Salamanca, Spain

<sup>c</sup>Department of Internal Medicine, General Hospital of Segovia, Segovia, Spain

**Corresponding Editor:** William Cameron, Ottawa, Canada

\*Corresponding author

E-mail address: mbelhassen@hotmail.com

(M. Belhassen-García)