



3D Models of Female Pelvis Structures Reconstructed and Represented in Combination with Anatomical and Radiological Sections

L. Asensio Romero¹ · M. Asensio Gómez¹ · A. Prats-Galino² · J. A. Juanes Méndez¹

Received: 1 December 2017 / Accepted: 2 January 2018 / Published online: 15 January 2018
© Springer Science+Business Media, LLC, part of Springer Nature 2018

Abstract

We present a computer program designed to visualize and interact with three-dimensional models of the main anatomical structures of the female pelvis. They are reconstructed from serial sections of corpse, from the Visible Human project of the Medical Library of the United States and from serial sections of high-resolution magnetic resonance. It is possible to represent these three-dimensional structures in any spatial orientation, together with sectional images of corpse and magnetic resonance imaging, in the three planes of space (axial, coronal and sagittal) that facilitates the anatomical understanding and the identification of the set of visceral structures of this body region. Actually, there are few studies that analyze in detail the radiological anatomy of the female pelvis using three-dimensional models together with sectional images, making use of open applications for the representation of virtual scenes on low cost Windows® platforms. Our technological development allows the observation of the main female pelvis viscera in three dimensions with a very intuitive graphic interface. This computer application represents an important training tool for both medical students and specialists in gynecology and as a preliminary step in the planning of pelvic floor surgery.

Keywords Three-dimensional models · Corpse sections visible human project · Radiological female pelvis anatomy · Corpse female pelvis anatomy · High resolution magnetic resonance · Computer development

Introduction

The female pelvis is one of the most difficult anatomical regions to understand in a live individual or in a corpse [1, 2]. It harbors organs of irregular morphology as well

as structures of the pelvic floor distributed in different planes, those are hard to represent and comprehend through two-dimensional images.

Along history the study of the human body has been carried out through the anatomical dissection of corpses, although it is known that there are some important post-mortem changes that can alter the anatomy. [3].

One of the main contributions for the morphological analysis of the human body, specially in the case of the female pelvis, has been the magnetic resonance imaging (MRI). This technique of imaging contributes to improve the analysis of the various pathologies and the suitable surgical approach in different fields of medicine. MRI is an excellent non-invasive diagnostic technique due to the multiplanar characteristic and the soft tissue differentiation capacity that achieves. Nevertheless, the individual examination of sectional images of a MRI sequence allows a simple vision [1].

The study of the female pelvis has evolved along with the available formats and technologies of the time [4]. This anatomical study of the bony pelvis and the muscular elements of the pelvic floor or perineum that harbor and hold the pelvic

This article is part of the Topical Collection on *Education & Training*

✉ L. Asensio Romero
lourdes90.ar@gmail.com

M. Asensio Gómez
mago59@usal.es

A. Prats-Galino
aprats@ub.edu

J. A. Juanes Méndez
jajm@usal.es

¹ Department of Human Anatomy and Histology, School of Medicine, University of Salamanca, Salamanca, Spain

² Department of Human Anatomy and Embryology, School of Medicine, University of Barcelona, Barcelona, Spain

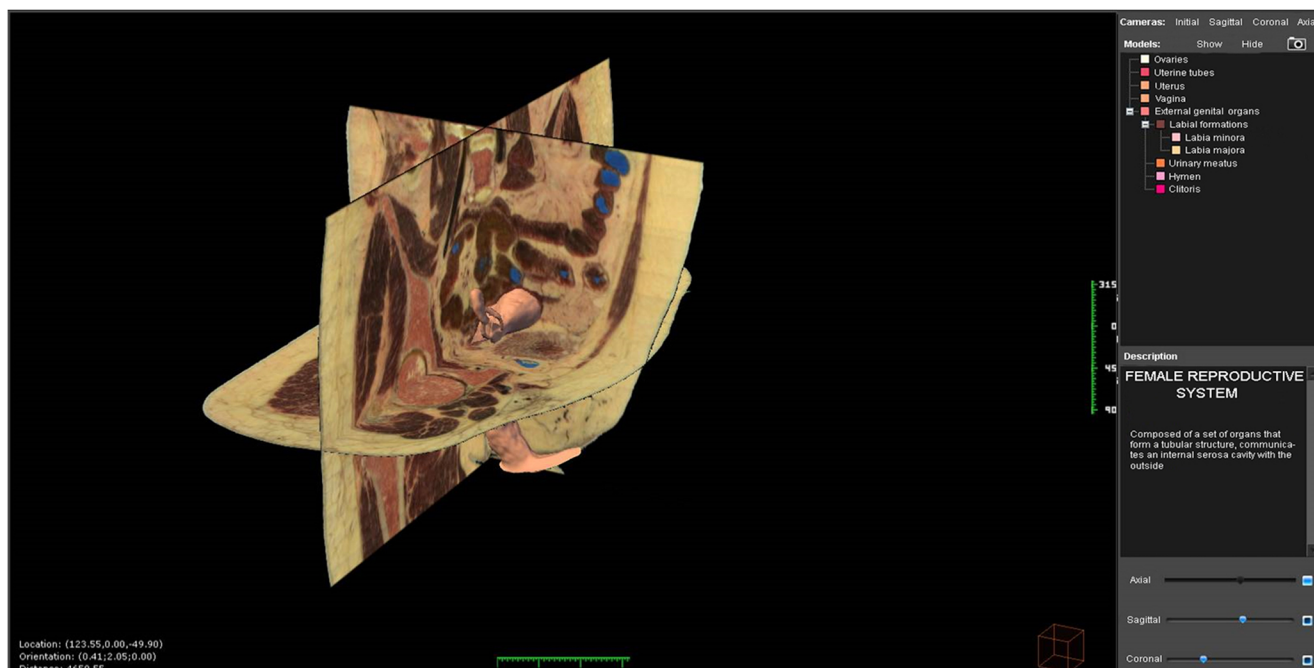


Fig. 1 Visualization of user's interface of the computer application

viscera, and constitute the perineum, are very important, for example, for a better understanding of functions such as urinary continence and urination [5].

Then, three-dimensional (3D) visualization of anatomical structures combined with corpse sections and together with volumetric MRI data establishes the most intuitive and clear kind of morphological analysis [6, 7].

Thus, the objective of this work is the 3D modeling of the main visceral structures of a normal female pelvis and its representation in an OS PC permitting its visualization and interaction. The use of this kind of techniques in the field of gynecology has recently enabled

us to get images that improve the anatomical knowledge of the female pelvis [2, 8]. Therefore, we develop a computer program based on 3D visualization and study of the anatomical structures of the female pelvis with simultaneous sections of corpse from the Visible Human project and MRI images in the three planes of space.

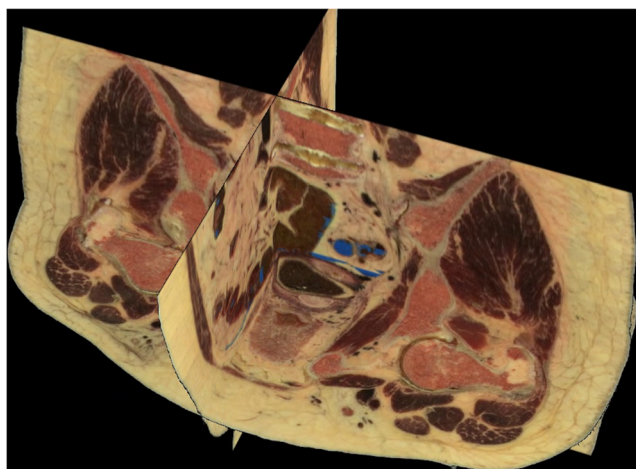


Fig. 2 Simultaneous visualization of three anatomical sections (axial, coronal and sagittal)

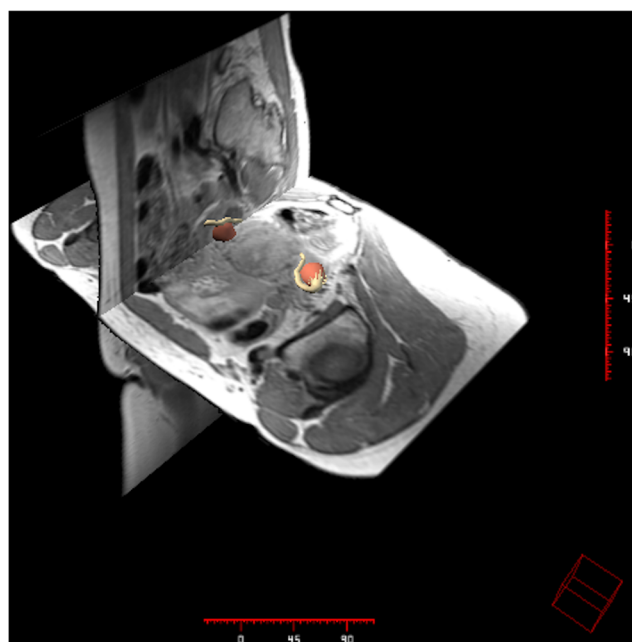


Fig. 3 Simultaneous visualization of three radiological sections (axial, coronal and sagittal)

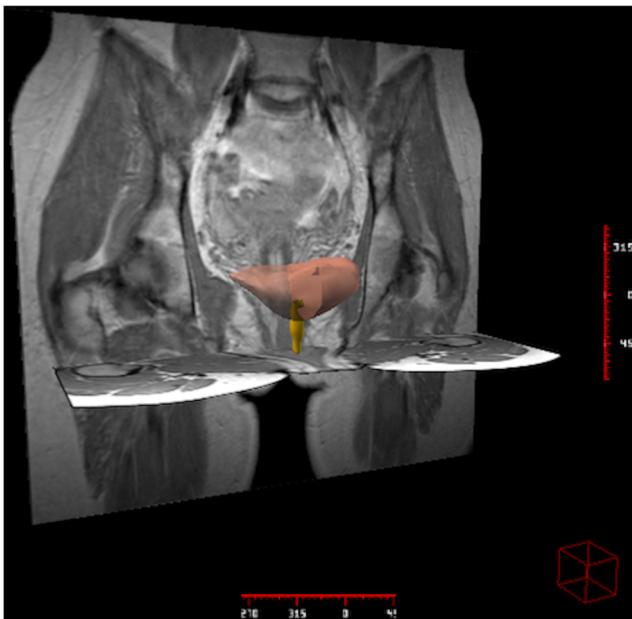


Fig. 4 Visualization of pelvic visceral 3D models in two radiological sections (axial, and coronal)

Methodology

Corpse sectional images

We obtained the corpse sectional images of multiple axial sections of 0,33 mm thick of high resolution obtained from a woman corpse from the Visible Human Female CD 2.0 Version® of the National Library of Medicine in the USA, under authorized license.

We used Autodesk Maya® for the volumetric non-probabilistic creation of anatomic structures.

The images were adjusted in size and format with Pixresizer Software version 2.0.4®.

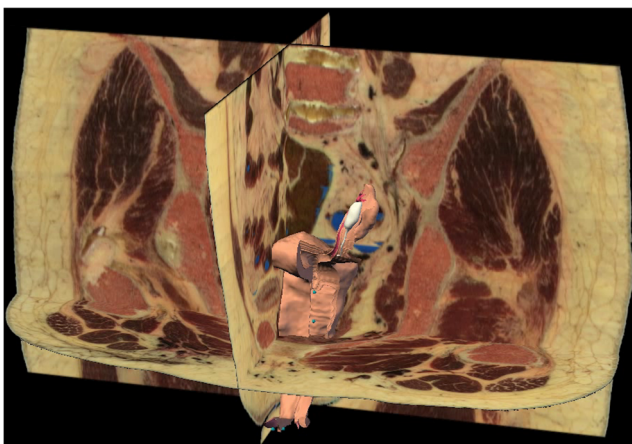


Fig. 5 Visualization of pelvic visceral 3D model in three anatomical sections (axial, coronal and sagittal)

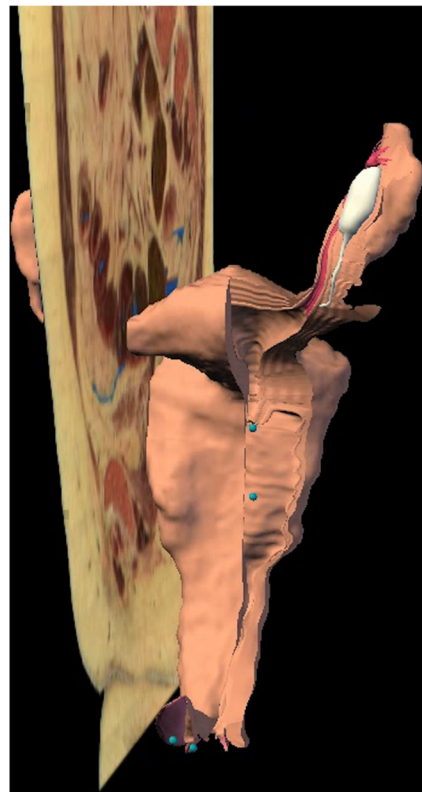


Fig. 6 Visualization of pelvic visceral 3D models in an anatomical section (sagittal)

The delimitation of the response area for the location of the target structure in every task was made through Image Mapper version 1.0®.

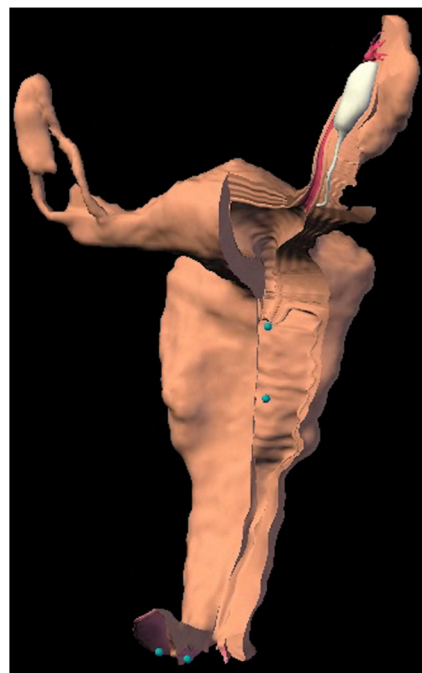


Fig. 7 Visualization of visceral model 3D

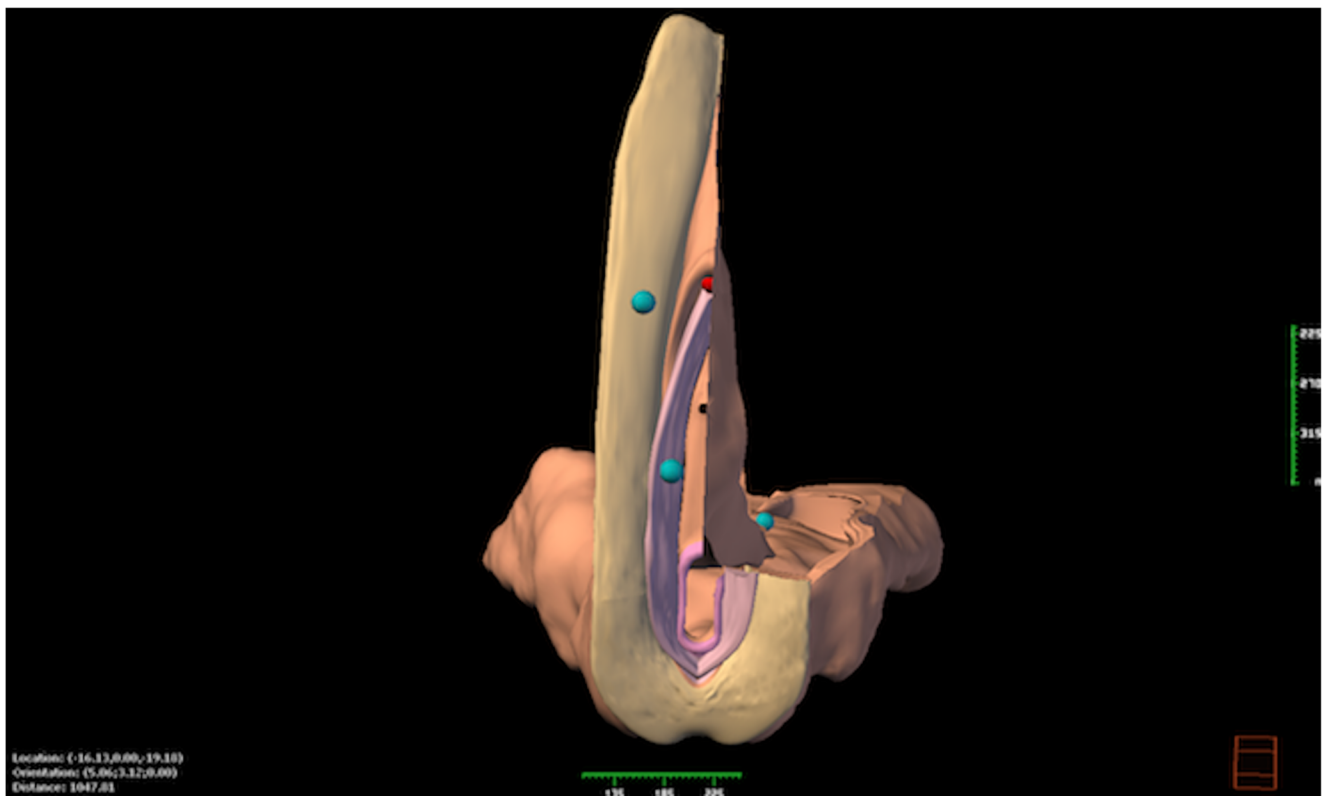


Fig. 8 Visualization of visceral model 3D

MRI sectional images

We acquire high-resolution images with a spacing of 0.5 mm of the pelvic region, enhanced in proton density. We get orthogonal sections from the three planes of space using a 1.5 Tesla scanner (HarmonyExpert, Siemens®) from a 29-year-old female volunteer with no known history of gynecological pathology. A volume was reconstructed from the DICOM files and saved in ANALYZE 7.5® format. The three volumes were aligned taking as reference the volume acquire in the axial plane. The regions of interest (ROIs) or “labels” were delimited in the isometric volumes of the anatomical structures to be reconstructed using a 3-D editor (Amira, 3.1; TGS Template Graphics Software®).

Programming

The computer application has been developed for Windows® platforms and programmed in Visual C++®.

For each 3D rebuilt model we elaborate an html file with a short anatomic description in order to complementing the information that will be showed in the computer application.

User's interface

The user's interface consists of the following areas: (Fig. 1).

- 3D visor, for the representation of different graphic elements (planes and models).
- Control area, with the different controls for the interaction with the sectional images and the models (visibility, color model).
- Scene selector, is a drop-down menu through which the virtual scene to represent can be selected.
- Descriptive table with a brief anatomical description of the selected 3D model.
- Plane control area that allows modifying its position and visibility.

Results

Our computer applications enable to visualize and interact simultaneously with:

- Sectional corpse and MRI images of the female pelvis selected at intervals of 5 mm, both in the three orthogonal axis of the space (axial, coronal and sagittal). (Figs. 2 and 3)
- 3D anatomical models of diverse structures of the female pelvis. (Figs. 4, 5, 6, 7, 8 and 9)

The graphic user's interface is very intuitive. It shows the different areas in order to interact with the anatomical viewer.

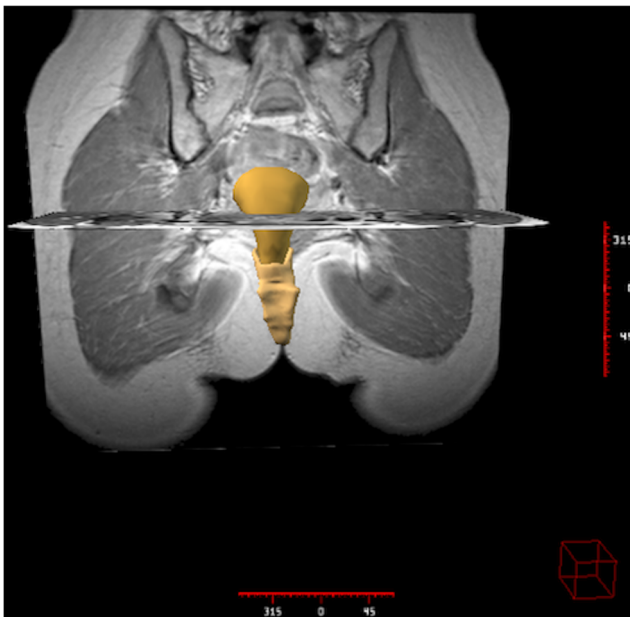


Fig. 9 Visualization of pelvic visceral 3D models in two radiological sections (axial, and coronal)

These options enable a 3D visualization of the anatomical structures at the user request. The corpse and MRI sections in the three planes of the space are taken as a reference. (Figs. 10 and 11).

Every interaction with the elements of the visual scene is made using the computer mouse, by placing the cursor on the visor. The resultant view of carrying out rotations, translations or

zoom may be stored in a file. It is possible to save the scene displayed in the visor as a bitmap (.bmp) format file with the option “capture image” represented with a camera icon. (Fig. 12).

The descriptive zone includes a brief anatomical description that complements the image shown by the application. The planes button is the screen where the user may interact with the visor and its configuration. They include the necessary controls to manage the sectional images displayed in the visor. There are three orientation planes: sagittal, axial and coronal. Each plane has a selection control to activate or deactivate its visibility. We can also move horizontally the cursor over the visor, changing the position of the selected plane. (Fig. 13).

All our computer system is controlled at the user’s will. Therefore, a real interaction between the computer and the user exists.

Our computer development is a meticulous and thorough elaborated teaching tool, so that the users may develop autonomously the whole process of medical training, especially in the field of gynecology. This will lead to a better knowledge and understanding of female pelvis, because the anatomical structures of this body region will be accessible to analysis from any spatial position and in three dimensions.

Discussion

The generation of 3D images of the human body is increasing in the last years. Its use has been generalized in different fields

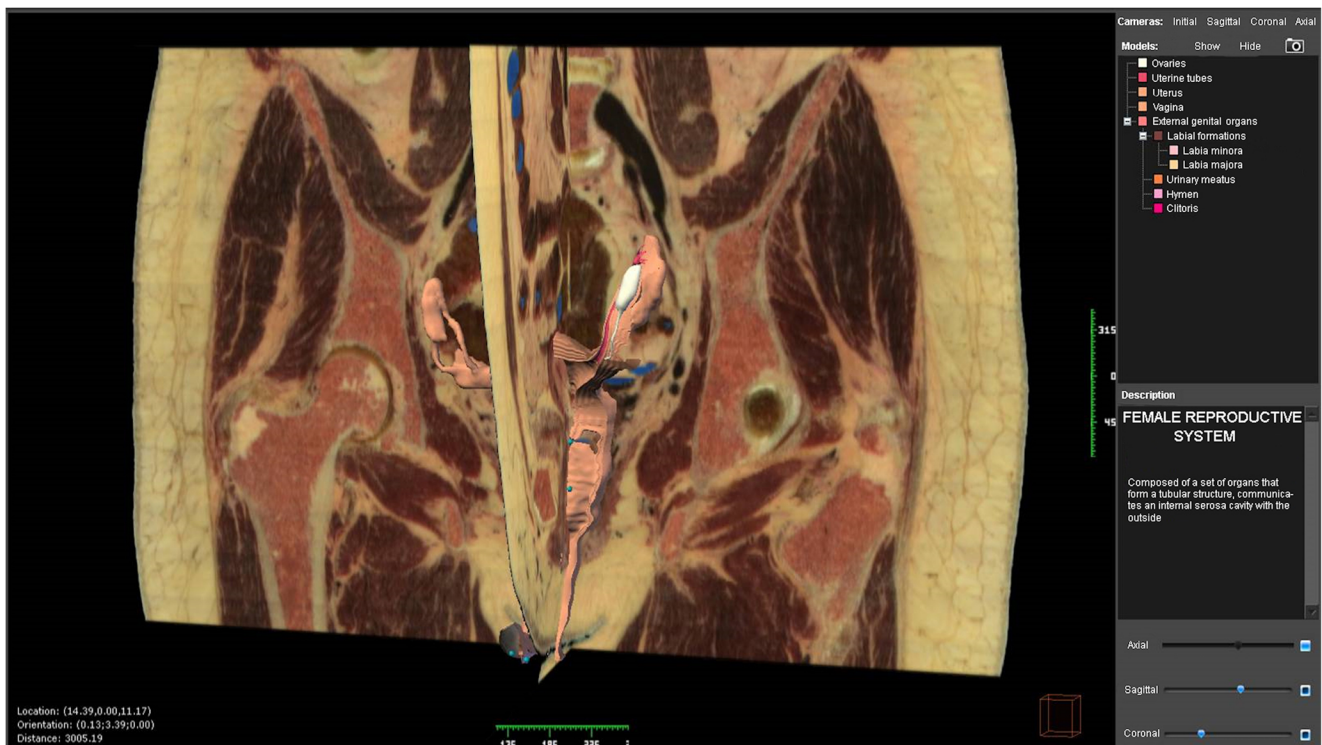


Fig. 10 User’s interface of the computer application developed

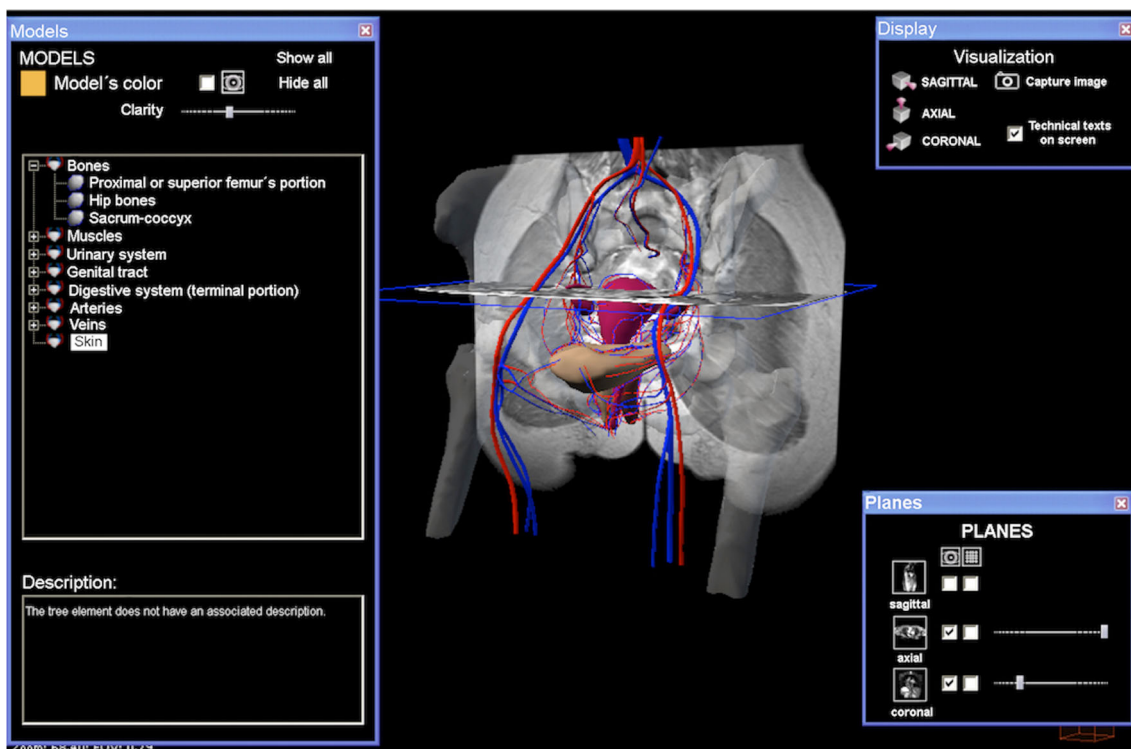


Fig. 11 User’s interface of the computer application developed

of medicine [4, 9–12]. The growing implementation of advanced computer applications in the visualization of 3D models of anatomical structures enables a better understanding of its structure and spatial relationships [13, 14].

Computer programs are a very useful teaching and training tool in all fields of medicine [2, 15].

Advances in computer technology and communication techniques have been incorporated into the field of teaching and training in medical sciences with the objective of increase the efficiency and productivity of both processes [12, 16–21].

The user’s interface is a set of components utilize by user to communicate with the program that is running on the computer. The user is the one who really manage the functioning of the computer program thanks to diverse usability instructions.

A good interface is easy to understand and handle, allowing users to carry out learning or training task in a fast and simplest way [14, 22].

Imaging studies can facilitate knowledge of the anatomy and diagnosis of pathological processes that affect anatomical structures of the pelvis [23, 24]. These techniques have

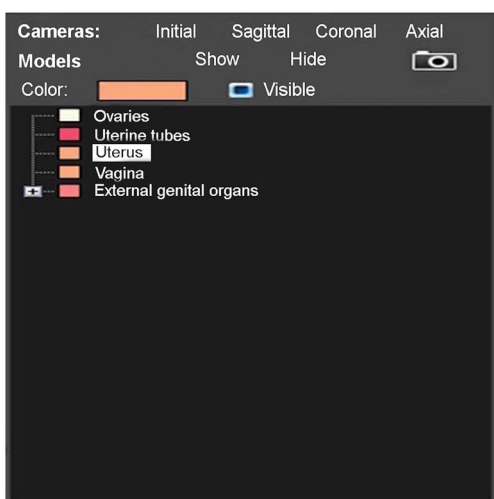


Fig. 12 User’s interface. Activation zone of 3D models

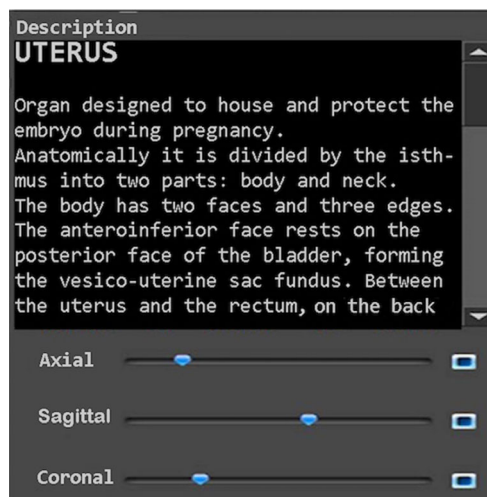


Fig. 13 User’s interface. Description zone of the selected 3D model and activation of serial anatomical sections of corpse

changed over time, not only in terms of diagnostic accuracy, but also as a fundamental decision element to establish a therapeutic plan [25, 26].

Therefore, in the diagnosis of the pathological processes of the pelvis, diagnostic imaging techniques have an important role. MRI offers multiple advantages over other imaging techniques such as computed tomography or transrectal ultrasound [27].

Consequently, MRI is an excellent tool in the evaluation and treatment of selected patients with gynecological, urological and coloproctologic pathologies [28]. This technique also allows planning a surgical intervention in certain patients [8, 26, 29–31]. Some therapeutic decisions can be made by acquiring direct experience in situations that would be difficult to perform in real life, such as the possibility of simulating a virtual surgical approach, through the use of different diagnostic imaging techniques like MRI.

In conclusion, female pelvis is an area of special anatomical complexity, so a 3D visualization of this region would make an easier learning. Therefore, our computer program is a good method of 3D visualization of the female pelvis, facilitating its anatomical evaluation, taking advantage of the graphic features that computers offer today. Our application allows the observation of different anatomic parts in a three-dimensional environment at the user's request based on the sections of corpse from the Visible Human Project and images of MRI with a very intuitive graphic interface. All of this has enabled us to establish virtual 3D models of the female pelvis from anatomic and radiological images arranged in series.

Compliance with Ethical Standards

Conflict of Interest L. Asensio Romero declares that she has no conflict of interest. M. Asensio Gómez declares that he has no conflict of interest. A. Prats-Galino declares that he has no conflict of interest. J. A. Juanes Méndez declares that he has no conflict of interest.

Ethical Approval All procedures performed in studies involving human participants were in accordance with the ethical standards of the institutional and/or national research committee and with the 1964 Helsinki declaration and its later amendments or comparable ethical standards. This article does not contain any studies with animals performed by any of the authors.

Informed Consent Informed consent was obtained from all individual participants included in the study.

References

- Pujol, S., Baldwin, M., Nassiri, J., Kikinis, R., and Shaffer, K., Using 3D modeling techniques to enhance teaching of difficult anatomical concepts. *Acad. Radiol.* 23(4):507–516, 2016. <https://doi.org/10.1016/j.acra.2015.12.012>.
- Legendre, G., Sahmoune Rachedi, L., Descamps, P., and Fernandez, H., Providing of a virtual simulator perineal anatomy (pelvic mentor®) in learning pelvic perineology: Results of a preliminary study. *J. Gynecol. Obstet. Biol. Reprod.* 44(1):72–77, 2014. <https://doi.org/10.1016/j.jgyn.2014.04.004>.
- Fang, B., Wu, Y., Chu, C., Li, Y., Luo, N., Liu, K., Tan, L., and Zhang, S., Creation of a virtual anatomy system based on Chinese visible human data sets. *Surg. Radiol. Anat.* 39(4):441–449, 2017. <https://doi.org/10.1007/s00276-016-1741-7>.
- Ghosh, S.K., Evolution of illustrations in anatomy: A study from the classical period in Europe to modern times. *Anat. Sci. Educ.* 8(2):175–188, 2015. <https://doi.org/10.1002/ase.1479>.
- Abdulaziz, M., Deegan, E.G., Kavanagh, A., Stothers, L., Pugash, D., and Macnab, A., Advances in basic science methodologies for clinical diagnosis in female stress urinary incontinence. *Can. Urol. Assoc. J.* 11(6,2):117–120, 2017. <https://doi.org/10.5489/cuaj.4583>.
- Balaya, V., Uhl, J.F., Lanore, A., Salachas, C., Samoyeau, T., Ngo, C., Bensaid, C., Cornou, C., Rossi, L., Douard, R., Bats, A.S., Lecuru, F., and Delmas, V., 3D modeling of the female pelvis by computer-assisted anatomical dissection: Applications and perspectives. *J. Gynecol. Obstet. Biol. Reprod.* 45(5):467–477, 2016. <https://doi.org/10.1016/j.jgyn.2016.01.006>.
- Shin, D.S., Jang, H.G., Hwang, S.B., Har, D.H., Moon, Y.L., and Chung, M.S., Two-dimensional sectioned images and three-dimensional surface models for learning the anatomy of the female pelvis. *Am. Assoc. Anatomists.* 6:316–323, 2013. <https://doi.org/10.1002/ase.1342>.
- Kraima, A.C., Smit, N.N., Jansma, D., Wallner, C., Bleys, R.L., van de Velde, C.J., Botha, C.P., and DeRuiter, M.C., Toward a highly-detailed 3D pelvic model: Approaching an ultra-specific level for surgical simulation and anatomical education. *Clin. Anat.* 26(3): 333–338, 2013. <https://doi.org/10.1002/ca.22207>.
- Ackerman, M.J., The visible human project®: From body to bits. *Conf. Proc. IEEE Eng. Med. Biol. Soc.* 2016:3338–3341, 2016. <https://doi.org/10.1109/EMBC.2016.7591442>.
- Noetscher, G.M., Yanamadala, J., Tankaria, H., Louie, S., Prokop, A., Nazarian, A., and Makarov, S.N., Computational human model VHP-FEMALE derived from datasets of the national library of medicine. *Conf. Proc. IEEE Eng. Med. Biol. Soc.* 2016:3350–3353, 2016. <https://doi.org/10.1109/EMBC.2016.7591445>.
- Yanamadala, J., Noetscher, G.M., Louie, S., Prokop, A., Kozlov, M., Nazarian, A., and Makarov, S.N., Multi-purpose VHP-female version 3.0 cross-platform computational human model. *Conf. Proc. IEEE Antennas Propag. (EuCAP)*. 2016:1–5, 2016. <https://doi.org/10.1109/EuCAP.2016.7481298>.
- Rea P.M., Advances in anatomical and medical visualisation. In Pinheiro MM, Simões D (ed) *Handbook of Research on Engaging Digital Natives in Higher Education Settings*. Aveiro, pp 244–264, 2016. <https://doi.org/10.4018/978-1-5225-0039-1.ch011>
- Berney, S., Bétrancourt, M., Molinari, G., and Hoyek, N., How spatial abilities and dynamic visualizations interplay when learning functional anatomy with 3D anatomical models. *Anat. Sci. Educ.* 8(5):452–462, 2015. <https://doi.org/10.1002/ase.1524>.
- Taberero Rico, R.D., Juanes Méndez, J.A., and Prats Galino, A., New generation of three-dimensional tools to learn anatomy. *J. Med. Syst.* 41(5):88, 2017. <https://doi.org/10.1007/s10916-017-0725-4>.
- An, G., Hong, L., Zhou, X.B., Yang, Q., Li, M.Q., and Tang, X.Y., Accuracy and efficiency of computer-aided anatomical analysis using 3D visualization software based on semi-automated and automated segmentations. *Ann. Anat.* 210:76–83, 2017. <https://doi.org/10.1016/j.aanat.2016.11.009>.
- Fenesi, B., Mackinnon, C., Cheng, L., Kim, J.A., and Wainman, B.C., The effect of image quality, repeated study, and assessment method on anatomy learning. *Anat. Sci. Educ.* 10(3):249–261, 2017. <https://doi.org/10.1002/ase.1657>.

17. Preece, D., Williams, S., Lam, R., and Weller, R., Let's get physical: Advantages of a physical model over 3D computer models and textbooks in learning imaging anatomy. *Anat. Sci. Educ.* 6(4): 216–224, 2013. <https://doi.org/10.1002/ase.1345>.
18. Estai, M., and Bunt, S., Best teaching practices in anatomy education: A critical review. *Ann. Anat. -Anatomischer Anzeiger.* 208: 151–157, 2016. <https://doi.org/10.1016/j.aanat.2016.02.010>.
19. Peterson, D.C., and Mlynarczyk, G.S., Analysis of traditional versus three-dimensional augmented curriculum on anatomical learning outcome measures. *Anat. Sci. Educ.* 9(6):529–536, 2016. <https://doi.org/10.1002/ase.1612>.
20. Trelease, R.B., From chalkboard, slides, and paper to e-learning: How computing technologies have transformed anatomical sciences education. *Anat. Sci. Educ.* 9(6):583–602, 2016. <https://doi.org/10.1002/ase.1620>.
21. Wohlrab, K., Jelovsek, E., and Myers, D., Incorporating simulation into gynecologic surgical training. *Am. J. Obstet. Gynecol.* 217(5): 522–526, 2017. <https://doi.org/10.1016/j.ajog.2017.05.017>.
22. Barbeito, A., Painho, M., Cabral, P., and O'Neill, J.G., Beyond digital human body atlases: Segmenting an integrated 3D topological model of the human body. *Int. J. E-Health Med. Commun. (IJEHMC).* 8(1):19–36, 2017. <https://doi.org/10.4018/IJEHMC.2017010102>.
23. Brown, K., Handa, V., Macura, K., and DeLeon, V., Three-dimensional shape differences in the bony pelvis of women with pelvic floor disorders. *Int. Urogynecol. J.: Including Pelvic Floor Dysfunction.* 24(3):431–439, 2013. <https://doi.org/10.1007/s00192-012-1876-y>.
24. Moore, C.W., Wilson, T.D., and Rice, C.L., Digital preservation of anatomical variation: 3D-modeling of embalmed and plastinated cadaveric specimens using μ CT and MRI. *Ann. Anat. - Anatomischer Anzeiger.* 209:69–75, 2017. <https://doi.org/10.1016/j.aanat.2016.09.010>.
25. Bertrand, M., Macri, F., Mazars, R., Droupy, S., Beregi, J., and Prudhomme, M., MRI-based 3D pelvic autonomous innervation: A first step towards image-guided pelvic surgery. *Eur. Radiol.* 24(8):1989–1997, 2014. <https://doi.org/10.1007/s00330-014-3211-0>.
26. Yiasemidou, M., Glassman, D., Mushtaq, F., Athanasiou, C., Williams, M.M., Jayne, D., and Miskovic, D., Mental practice with interactive 3D visual aids enhances surgical performance. *Surg. Endosc. Interventional Techniques.* 31(10):4111–4117, 2017. <https://doi.org/10.1007/s00464-017-5459-3>.
27. Peng, Y., Khavari, R., Nakib, N.A., Boone, T.B., and Zhang, Y., Assessment of urethral support using MRI-derived computational modeling of the female pelvis. *Int. Urogynecol. J.* 27(2):205–212, 2016. <https://doi.org/10.1007/s00192-015-2804-8>.
28. Chen, L., Lenz, F., Alt, C.D., Sohn, C., De Lancey, J.O., and Brocker, K.A., MRI visible Fe₃O₄ polypropylene mesh: 3D reconstruction of spatial relation to bony pelvis and neurovascular structures. *Int. Urogynecol. J. Pelvic Floor Dysfunct.* 28(8):1131–1138, 2017. <https://doi.org/10.1007/s00192-017-3263-1>.
29. Doumouchtsis, S.K., Nazarian, D.A., Gauthaman, N., Durnea, C.M., and Munneke, G., Three-dimensional volume rendering of pelvic models and paraurethral masses based on MRI cross-sectional images. *Int. Urogynecol. J.* 28:1–9, 2017. <https://doi.org/10.1007/s00192-017-3317-4>.
30. Giannini, A., Iodice, V., Picano, E., Russo, E., Zampa, V., Ferrari, V., and Simoncini, T., Magnetic resonance imaging-based three dimensional patient-specific reconstruction of uterine fibromatosis: Impact on surgery. *J. Gynecol. Surg.* 33(4):138–144, 2017. <https://doi.org/10.1089/gyn.2016.0119>.
31. Smit, N., Lawonn, K., Kraima, A., DeRuiter, M., Sokooti, H., Bruckner, S., Eisemann, E., and Vilanova, A., PelVis: Atlas-based surgical planning for oncological pelvic surgery. *IEEE Trans. Vis. Comput. Graph.* 23(1):741–750, 2017. <https://doi.org/10.1109/TVCG.2016.2598826>.